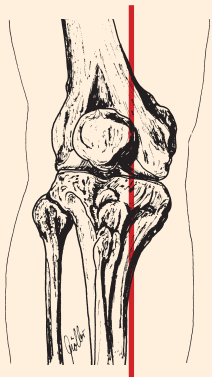
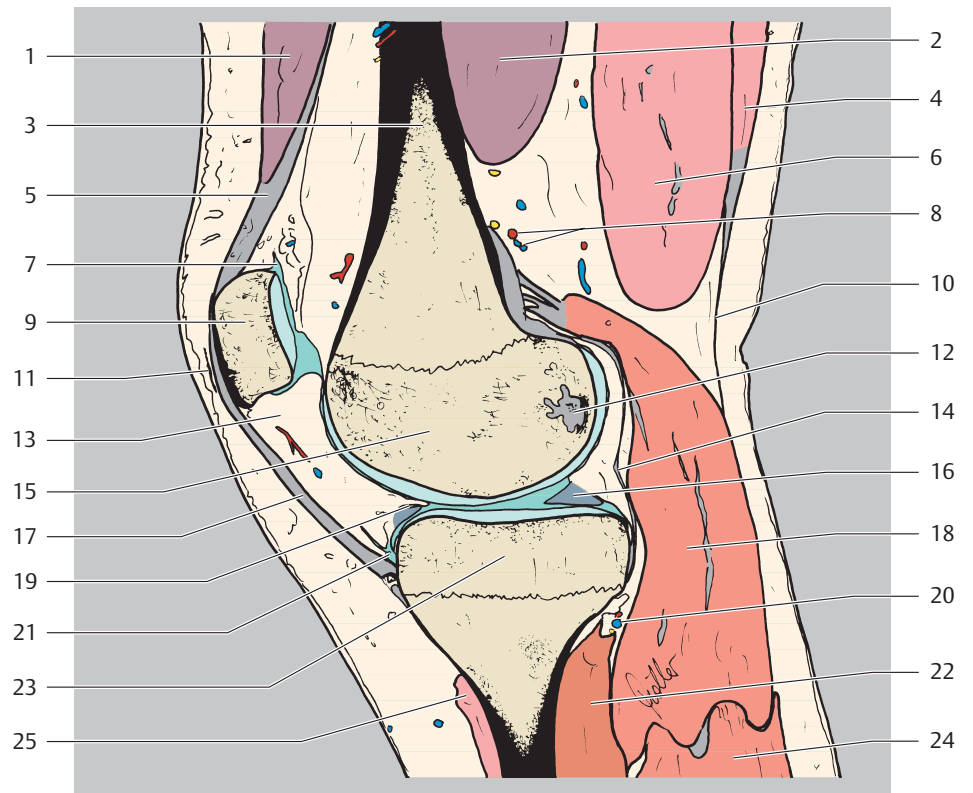


- 1 M. rectus femoris
- 2 M. vastus medialis
- 3 Femur (Corpus)
- 4 M. semitendinosus
- 5 Quadrizepssehne
- 6 M. semimembranosus
- 7 Bursa suprapatellaris
- 8 A. + V. superior medialis genus
- 9 Patella
- 10 Fascia cruris
- 11 Bursa praepatellaris (subcutanea)
- 12 Lig. cruciatum posterius (Ansatz)
- 13 infrapatellarer Fettkörper (Hoffa-Fettkörper)
- 14 Capsula articularis
- 15 Femur (Condylus medialis)
- 16 Innenmeniskus (Hinterhorn)
- 17 Lig. patellae
- 18 M. gastrocnemius (Caput mediale)
- 19 Lig. transversum genus
- 20 A. + V. inferior medialis genus
- 21 Bursa infrapatellaris profunda
- 22 M. popliteus
- 23 Condylus medialis tibiae
- 24 M. gastrocnemius (Caput laterale)
- 25 M. sartorius (Ansatz, Teil des Pes anserinus superficialis)



proximal
 ventral □ dorsal
 distal

